Oral Oncology 64 (2017) 73–77

Contents lists available at ScienceDirect

Oral Oncology

journal homepage: www.elsevier.com/locate/oraloncology

Refining the definition of mandibular osteoradionecrosis in clinical trials: The cancer research UK HOPON trial (Hyperbaric Oxygen for the Prevention of Osteoradionecrosis)

Richard Shaw [a,b,*], Binyam Tesfaye [b], Matt Bickerstaff [b], Paul Silcocks [b], Christopher Butterworth [a,c]

[a] Department of Molecular and Clinical Cancer Medicine, University of Liverpool & Head & Neck Division, Aintree University Hospital NHS Foundation Trust, Liverpool L9 7AL, UK
[b] Cancer Research UK Liverpool Cancer Trials Unit, University of Liverpool Cancer Research Centre, University of Liverpool, Block C Waterhouse Building, 1-3 Brownlow Street, L69 3GL, UK
[c] Department of Restorative Dentistry, Liverpool University Dental Hospital, Pembroke Place, Liverpool L3 5PS, UK

ARTICLE INFO

Article history:
Received 15 November 2016
Received in revised form 28 November 2016
Accepted 3 December 2016
Available online 10 December 2016

Keywords:
Osteoradionecrosis
Mandible
Definition
Classification
Clinical trial

ABSTRACT

Introduction: Mandibular osteoradionecrosis (ORN) is a common and serious complication of head and neck radiotherapy for which there is little reliable evidence for prevention or treatment. The diagnosis and classification of ORN have been inconsistently and imprecisely defined, even in clinical trials.
Methods: A systematic review of diagnosis and classifications of ORN with specific focus on clinical trials is presented. The most suitable classification was evaluated for consistency using blinded independent review of outcome data (clinical photographs and radiographs) in the HOPON trial.
Results: Of 16 ORN classifications found, only one (Notani) appeared suitable as an endpoint in clinical trials. Clinical records of 217 timepoints were analysed amongst 94 randomised patients in the HOPON trial. The only inconsistency in classification arose where minor bone spicules (MBS) were apparent, which occurred in 19% of patients. Some trial investigators judged MBS as clinically unimportant and not reflecting ORN, others classified as ORN based on rigid definitions in common clinical use. When MBS was added as a distinct category to the Notani classification this ambiguity was resolved and agreement between observers was achieved.
Discussion: Most definitions and clinical classifications are based on retrospective case series and may be unsuitable for prospective interventional trials of ORN prevention or treatment. When ORN is used as a primary or secondary outcome in prospective clinical trials, the use of Notani classification with the additional category of MBS is recommended as it avoids subjectivity and enhances reliability and consistency of reporting.

© 2016 Elsevier Ltd. All rights reserved.

Introduction

Mandibular osteoradionecrosis (ORN) is a common complication of radiotherapy for head and neck malignancy whereby the bone undergoes necrosis, becoming exposed. This is usually symptomatic and may cause intra- or extra-oral fistulae, infection, pain and eventually pathological fracture [1]. The consequences of these complications include malnutrition, opiate dependency, haemorrhage, sepsis, with progressive disfigurement and deterioration in quality of life. The incidence of head and neck cancer, survival and proportion receiving radiotherapy are all increasing, in part, due to Human Papillomavirus related cases [2,3]. As such, the 'at risk' population for ORN is increasing and it has justifiably become a focus for clinical trials.

Classifications of mandibular ORN vary significantly in their aims but have been developed in order to help the clinician categorise and manage ORN in routine clinical practice rather than as endpoints in clinical trials. The emergence of formally conducted prospective randomized trials addressing ORN, such as HOPON [4], DAHANCA21 [4], ORN96 [5] & those of Delanian [6], highlights the requirement for more objective and valid endpoints. This would facilitate reproducibility across multiple trial sites and validation by independent blinded panels even in the absence of the patient, irrespective of the treatment arm assigned. Suggested criteria for definition and classification of ORN in clinical trials are listed in Table 1.

* Corresponding author at: Department of Molecular and Clinical Cancer Medicine, University of Liverpool & Head & Neck Division, Aintree University Hospital NHS Foundation Trust, Liverpool L9 7AL, UK.
E-mail address: richard.shaw@liverpool.ac.uk (R. Shaw).

http://dx.doi.org/10.1016/j.oraloncology.2016.12.002
1368-8375/© 2016 Elsevier Ltd. All rights reserved.

Table 1
Criteria for definition and classification of ORN in clinical trials.

	Domain	Criteria
a	Response	Does not assume outcome or response to the use of a defined prior treatment modality or protocol
b	Trend	Can be completed at a single time point and without knowledge of prior ORN or future progression/ prognosis
c	Prescription	Do not make assumptions about indications for, or methods of, subsequent treatment
d	Blinding	Can be readily reproduced for validation by independent blinded assessor or panel
e	Precision	Are not subject to subjectivity or vague definitions
f	Validation	Not dependent on unvalidated patient reported outcomes or symptom severity
g	Exposure	Mandates the presence of exposed bone, ie. presence of radiological changes *alone* are insufficient to diagnose ORN

The HOPON trial (Hyperbaric Oxygen in the Prevention of Osteoradionecrosis) addresses the prophylactic benefit of hyperbaric oxygen in preventing osteoradionecrosis accompanying surgical procedures to the irradiated mandible. Patients are eligible for HOPON who require dental extractions in the posterior mandible or implant placement and are at high risk of ORN following radiotherapy for head and neck malignancy. In developing the protocol for the HOPON trial, it has become apparent that a robust classification of osteoradionecrosis has not yet been well resolved within clinical trials.

The aims of this study are to review, refine and validate suitable classifications of ORN within the setting of clinical trials. A systematic review of published classifications of mandibular ORN will be conducted with specific reference to their suitability as a clinical trial endpoint, with reference to the criteria listed in Table 1. These criteria have been assembled as an assumed gold-standard in trials with osteoradionecrosis as an endpoint. The most suitable method (s) will subsequently validated using data from the CR-UK HOPON trial (ISRCTN39634732), focusing on inconsistencies in categorization by a blinded independent expert review panel.

Methods

Systematic review

The published literature was reviewed for articles relating to classification of mandibular osteoradionecrosis 1970–2016. Pubmed was searched for articles using the terms "osteoradionecrosis", "mandible", "classification", "definition" and also with Mesh term "Osteoradionecrosis" and Mesh subheadings: "diagnosis", "analysis" and "classification". 350 resultant manuscripts in the English language were hand sorted, and cross-checked by scanning their reference lists. The criteria for selection were original, independent and distinct definitions and classifications of mandibular osteoradionecrosis. The 13 resultant articles that presented original classifications were additionally subject to scrutiny according to criteria laid out above and this data tabulated (Table S1). Additionally, the classification of mandibular ORN from the last three NIH Common Terminology Criteria for Adverse Events (CTCAE) [7–9] were separately tabulated (Table S2). The classification method most nearly fitting the criteria established in Table 1, was used in the second part of the study.

Validation

Anonymised patient records (clinical photographs and radiographs) from 94 patients randomised to the HOPON trial were reviewed independently by two blinded independent clinicians (RJS & CB). Cases were classified according to Notani et al. [10] and this was compared with the research site principal investor's assessment as annotated on the trial clinical record forms (CRFs). These records constituted a clinical photograph at 3, 6 and 12 month post-surgery time-points, and accompanying radiographs for the 6 month time-point (and 3 or 12 months, if ORN was clinically diagnosed). A dedicated software package on the trials unit's web portal was created so that both clinicians could independently access paired clinical photographs and radiographs for the defined endpoints for each patient. Any cases with discrepancies within the 3 independent assessments, or with any comments highlighting difficulty in classifying outcome in the free-text were noted for further analysis. Due to some incomplete data and immaturity of all data collection (and exclusion of two ineligible patients), a total of 217 clinical assessments were reviewed from a potential total of 336 (65% complete). The photographs and radiographs from each assessment were made *without* knowledge of timing or of which arm of the trial (HBO vs standard therapy) the patients was in, as the trial is ongoing at the time of writing.

Results

Systematic review: Definition of ORN

Many authors offer a description [11] rather than a definition of ORN, however a number of subtly differing definitions have been offered in the published literature. The cited definitions found in the literature generally appear to originate from three published versions [12–14]. Harris [12] defines mandibular ORN as "*exposed irradiated bone that fails to heal over a period of 3 months in the absence of local tumour*". Marx [13] offers a definition of "*an area greater than 1cm of exposed bone in a field of radiation that has failed to show any evidence of healing for at least 6 months*". The definitions of ORN show some consensus around an area of exposed bone for a minimum time period in an irradiated field and in the absence of tumour. The specific extent of exposed bone or time period specified vary and are presented in Table 2. Store and Boysen [14] include radiological change <u>without</u> exposed bone within diagnostic criteria, whilst this is specifically excluded by Harris & Marx [12,13] so this is evidently an area of controversy.

Classification of ORN

Although there was evident overlap between the principles of classification seen, 13 distinct classifications [10,11,13–23] (Table S1) were identified between 1983 and 2015 and 3 differing classifications were offered by CTCAE (Table S2) in 1999, 2006 and 2010. None of the peer reviewed publications were designed with the stated aim to evaluate treatments under investigation in prospective clinical trials, and indeed all were evaluated retrospectively from their authors' own institutional case series. The degree to which the classifications met the specified criteria varied considerably. As the Notani et al. [10] classification does not rely on assumptions about response to previous treatment or subsequent prescription bias, additionally it does not assume knowledge of

Table 2
Common diagnostic criteria for mandibular ORN.

Criteria	Specified thresholds
Presence of exposed bone [12,13]	Minimum dimension 1 cm [13]
Previously irradiated [12–14]	*(dose not specified in any definition)*
Minimum period of exposed bone	2 months [25,26] 3 months [12,27,28] 6 months [13]
Absence of recurrent tumour [12–14]	*(diagnostic criteria not stated in any definition)*

worsening or improving condition, it was judged to be the best fit for these criteria. As Notani relies on anatomical landmarks and mandates exposed bone that may be subject to clinical photographs, it lends itself better to remote and blinded review.

Validation

In most cases the HOPON site principal investigators' assessment agreed with the blinded clinicians using the Notani et al. [10] classification. However, in 24 of 217 these endpoint assessments (11.5%), representing 10 of 94 patients (19.1%), there was discordance. This was due to the presence very small areas of exposed bone leading to inconsistent recording between Notani 1 ORN and healed outcomes. These cases were subsequently termed "minor bone spicules" (MBS) and typical cases are illustrated in Figs. 1–3. Some trial investigators judged MBS as clinically unimportant and not reflecting ORN, others classified as ORN based on rigid definitions in common clinical use.

After identifying the dimensions of bone exposure creating inconsistencies between clinicians, MBS was subsequently defined as small spicules (<20 mm^2) of bone remaining through mucosal breaches in the absence of radiographic abnormalities. Other than the MBS cases, there was 100% agreement between site investigators and both blinded clinicians as to the diagnosis of ORN, and the classification of ORN between Notani 1, 2 and 3, which is not considered further in this manuscript. Of the 187 assessments classed as healed by the site investigators, 6 were classed as MBS after review. Of 26 cases classed by site investigators as Notani 1 ORN, 18 were reclassified on review as MBS and one reclassified as healed. Following adoption of this protocol, and subsequent reclassification with further blinded review, in all 217 time-points and 94 patients, there was 100% convergence between blinded investigators.

Fig. 2.

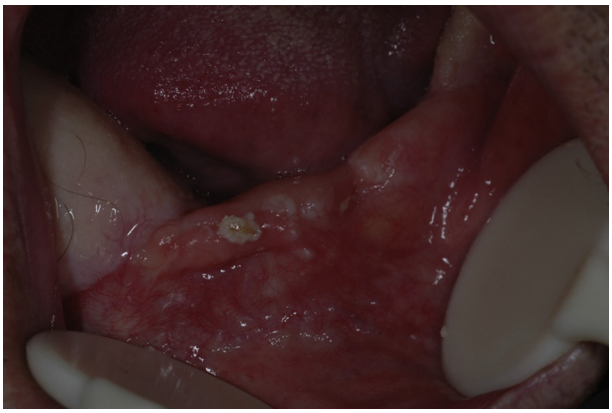

Fig. 3.

Discussion

We present a refined classification of Mandibular ORN that incorporates dimensions of exposed bone, fixed anatomical landmarks and defined time intervals. This reflects the outcome of a systematic review and detailed internal validation, at least for consistency in categorization to presence and grade of ORN, using the interim analysis data from a large clinical trial. In this regard, the classification offers an important advance over those that have been developed only using retrospective case series, and that are reliant on subjective assessments, predictions and vague class boundaries. Scrutiny of those class boundaries employed (which would include ORN involvement beyond ID nerve, fistula, as well as 20 mm^2 as a cut-off) will understandably invite criticisms of their arbitrary nature, or the degree to which they are patient-centered. The authors' impression that MBS cases are asymptomatic and heal uneventfully will be validated only with the publication of long term trial outcomes. However, the precise and measurable criteria suggested offer reproducibility and present a logical progression of clinical severity that evidently lends itself to trials better than other available options.

Fig. 1. Typical examples of cases classified as Minor Bone Spicules (MBS) as various clinical endpoints following recruitment to the HOPON trial. Although each case has exposed bone and incomplete mucosal healing, the total surface area of bone <20 mm^2. Corresponding radiographs are available and do not show radiological changes consistent with ORN).

After wider consultation, peer review from the National Cancer Research Institute H&N Clinical Studies Group, and discussion with the HOPON Trial Steering Committee, it was felt that MBS should be used as an additional refinement to Notani class, in order to reinforce the consistency of reporting for the trial primary endpoint. Thus, an upper size limit is established, e.g. 4×5 mm or 10×2 mm, such that lesions larger than or equal to 20 mm^2 would therefore be classified as ORN and graded in severity according Notani 1, 2 or 3 depending on radiographic changes, depth of bone necrosis and other factors. This trial protocol endpoint is illustrated in Fig. 4, and was subsequently agreed by the HOPON Independent Data Monitoring Committee. Subsequently the protocol amendment was approved by both Research Ethics Committee (REC) and the UK Medicines and Healthcare Regulatory Authority (MHRA).

The application of this refined classification was greatly facilitated by the HOPON protocol which mandates clinical measurement and photograph of the largest area of exposed bone in two

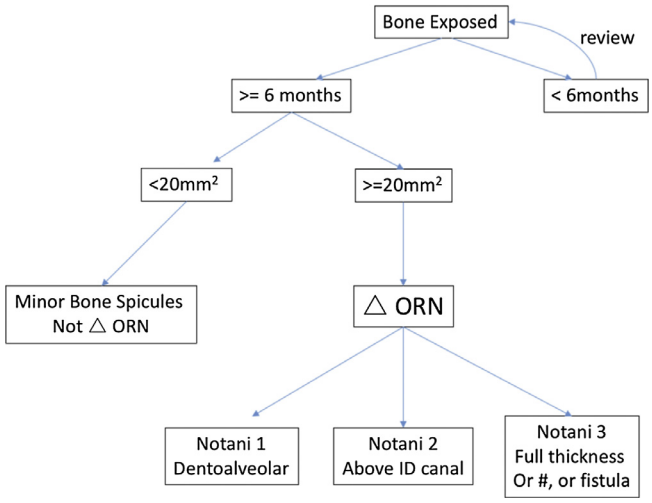

Fig. 4. Modified Notani ORN classification incorporating MBS. Not ORN: mucosal healing, or MBS <20 mm^2, or < 6 months. ORN: exposed bone ⩾20 mm^2 and ⩾6 months through oral mucosa or facial skin, excluding malignancy, within field of prior radiotherapy, further classified: Notani 1: ORN confined to alveolar bone. Notani 2: limited to the alveolar bone and/or above the level of the inferior alveolar canal. Notani 3: ORN under the lower part of the inferior alveolar canal, with fistula or bone fracture (Differentiation between Notani 1, 2 and 3 will usually be dependent on concurrent clinical and radiographic evidence).

dimensions using an in-field ruler. The potential validity of MBS as an outcome is reinforced by a comparable approach taken in the definitions offered by Marx [13], Coffin [16] and Morton [21]. The presumptive classification of MBS as 'healed' in all such cases, will be validated only by subsequent confirmation with longer term clinical review. Importantly, the use of MBS category may avoid misleading over-diagnosis of clinically significant ORN as the main trial outcome. This classification could be used in future trials of ORN, whether, prevention or therapy, either as an inclusion criterion or endpoint. In the light of the inadequacies of the CTCAE criteria for ORN classification, it might also have value as a secondary endpoint in head and neck trials including radiotherapy where jaw osteoradionecrosis might be an important finding.

The difficulty in classifying ORN raises some issues for the impact and applicability of the few trials already published in this field. Marx et al. [24] used the presence of 'exposed bone' at the study socket after 6 months as the primary endpoint for the 1985 ORN prevention after extraction study. Presumably, some of the ORN outcomes might have reflected only MBS. Similarly, the ORN96 trial [5] included patients with subtle radiographic changes but without exposed bone (thus defined as ORN) as eligible for randomisation in the trial. The same trial reported <u>any</u> area of bone exposure as ORN in its outcome measures, again raising the issue that different investigators might have had difficulty with allocating to healed versus ORN with MBS cases. Almost 20% of patients in the HOPON trial had MBS which was seemingly clinically insignificant, asymptomatic and with normal radiographs. The reporting of these cases was highly inconsistent despite site investigators all being given the same instructions and CRFs. This highlights concerns about trial endpoints in this field commonly not being reproducible, but also with potentially misleading outcomes not accurately reflecting clinical severity. The difficulty in reporting and interpreting these trials highlights the importance of consistent, transparency and reproducible classification.

Although there is a paucity of unbiased and reliable evidence for the management of ORN, adopting reliable and consistently reported clinical outcome measures will greatly enhance the impact of future clinical trials. We believe the modified Notani classification as described above offers significant advantages in this regard.

Funding

The HOPON Trial is funded by Cancer Research UK (CRUK CTAAC: C23033/A12122 & FSC: C23033/A9397).

Conflict of interest

None.

Acknowledgements

HOPON Independent Data Monitoring Committee: Mr. Jim Paul, Cancer Research UK. Clinical Trials Unit Glasgow; Mr. Jeremy McMahon, Southern General Hospital Glasgow; Dr. Gerry Robertson, Beatson West of Scotland Cancer Centre Glasgow.

HOPON Trial Steering Committee: Mrs. Sarah Brown, Clinical Trials Reserch Unit, University of Leeds; Dr. Richard Simcock, Sussex Cancer Centre, Brighton; Dr. Mark Glover, Hyperbaric Medicine Unit, Chichester; Dr Syed Hussain, Department of Molecular & Clinical Cancer Medicine, University of Liverpool; Mr. Dominic Macareavy and Mr. John Richardson (Independent Lay Members).

Appendix A. Supplementary material

Supplementary data associated with this article can be found, in the online version, at http://dx.doi.org/10.1016/j.oraloncology.2016.12.002.

References

[1] Dhanda J, Pasquier D, Newman L, Shaw R. Current concepts in osteoradionecrosis after head and neck radiotherapy. Clin Oncol (R Coll Radiol) 2016.
[2] McCarthy CE, Field JK, Rajlawat BP, Field AE, Marcus MW. Trends and regional variation in the incidence of head and neck cancers in England: 2002 to 2011. Int J Oncol 2015;47:204–10.
[3] Schache AG, Powell NG, Cuschieri KS, Robinson M, Leary S, Mehanna H, et al. HPV-related oropharynx cancer in the United Kingdom: an evolution in the understanding of disease etiology. Cancer Res 2016.
[4] Shaw R, Forner L, Butterworth C, Jansen E, Hillerup S, Nutting C, et al. Randomised controlled trials in HBO: "A call to arms" for HOPON & DAHANCA-21. Br J Oral Maxillofac Surg 2011;49:76–7.
[5] Annane D, Depondt J, Aubert P, Villart M, Gehanno P, Gajdos P, et al. Hyperbaric oxygen therapy for radionecrosis of the jaw: a randomized, placebo-controlled, double-blind trial from the ORN96 study group. J Clin Oncol 2004;22:4893–900.
[6] Delanian S, Chatel C, Porcher R, Depondt J, Lefaix JL. Complete restoration of refractory mandibular osteoradionecrosis by prolonged treatment with a pentoxifylline-tocopherol-clodronate combination (PENTOCLO): a phase II trial. Int J Radiat Oncol Biol Phys 2011;80:832–9.
[7] CTCAE version 2.0; 1999.
[8] CTCAE version 3.0; 2006.
[9] CTCAE version 4.0; 2010.
[10] Notani K, Yamazaki Y, Kitada H, Sakakibara N, Fukuda H, Omori K, et al. Management of mandibular osteoradionecrosis corresponding to the severity of osteoradionecrosis and the method of radiotherapy. Head Neck 2003;25:181–6.
[11] Epstein JB, Wong FL, Stevenson-Moore P. Osteoradionecrosis: clinical experience and a proposal for classification. J Oral Maxillofac Surg 1987;45:104–10.
[12] Harris M. The conservative management of osteoradionecrosis of the mandible with ultrasound therapy. Br J Oral Maxillofac Surg 1992;30:313–8.
[13] Marx RE. A new concept in the treatment of osteoradionecrosis. J Oral Maxillofac Surg 1983;41:351–7.
[14] Store G, Boysen M. Mandibular osteoradionecrosis: clinical behaviour and diagnostic aspects. Clin Otolaryngol Allied Sci 2000;25:378–84.
[15] Clayman L. Clinical controversies in oral and maxillofacial surgery: Part two. Management of dental extractions in irradiated jaws: a protocol without hyperbaric oxygen therapy. J Oral Maxillofac Surg 1997;55:275–81.
[16] Coffin F. The incidence and management of osteoradionecrosis of the jaws following head and neck radiotherapy. Br J Radiol 1983;56:851–7.

[17] Glanzmann C, Gratz KW. Radionecrosis of the mandibula: a retrospective analysis of the incidence and risk factors. Radiother Oncol 1995;36:94–100.
[18] He Y, Liu Z, Tian Z, Dai T, Qiu W, Zhang Z. Retrospective analysis of osteoradionecrosis of the mandible: proposing a novel clinical classification and staging system. Int J Oral Maxillofac Surg 2015;44:1547–57.
[19] Karagozoglu KH, Dekker HA, Rietveld D, de Bree R, Schulten EA, Kantola S, et al. Proposal for a new staging system for osteoradionecrosis of the mandible. Med Oral Patol Oral Cir Bucal 2014;19. e433-7.
[20] Lyons A, Osher J, Warner E, Kumar R, Brennan PA. Osteoradionecrosis – a review of current concepts in defining the extent of the disease and a new classification proposal. Br J Oral Maxillofac Surg 2014;52:392–5.
[21] Morton ME. Osteoradionecrosis: a study of the incidence in the North West of England. Br J Oral Maxillofac Surg 1986;24:323–31.
[22] Schwartz HC, Kagan AR. Osteoradionecrosis of the mandible: scientific basis for clinical staging. Am J Clin Oncol 2002;25:168–71.
[23] Tsai CJ, Hofstede TM, Sturgis EM, Garden AS, Lindberg ME, Wei Q, et al. Osteoradionecrosis and radiation dose to the mandible in patients with oropharyngeal cancer. Int J Radiat Oncol Biol Phys 2013;85:415–20.
[24] Marx RE, Johnson RP, Kline SN. Prevention of osteoradionecrosis: a randomized prospective clinical trial of hyperbaric oxygen versus penicillin. J Am Dent Assoc 1985;111:49–54.
[25] Beumer 3rd J, Curtis T, Harrison RE. Radiation therapy of the oral cavity: sequelae and management, part 2. Head Neck Surg 1979;1:392–408.
[26] Hutchison IL, Cope M, Delpy DT, Richardson CE, Harris M. The investigation of osteoradionecrosis of the mandible by near infrared spectroscopy. Br J Oral Maxillofac Surg 1990;28:150–4.
[27] Beumer 3rd J, Harrison R, Sanders B, Kurrasch M. Preradiation dental extractions and the incidence of bone necrosis. Head Neck Surg 1983;5:514–21.
[28] Morrish Jr RB, Chan E, Silverman Jr S, Meyer J, Fu KK, Greenspan D. Osteonecrosis in patients irradiated for head and neck carcinoma. Cancer 1981;47:1980–3.